

Immunohistochemical evaluation of metallothionein in palatal mucosal cells of mice treated with 4NQO

Maria Cássia Ferreira de Aguiar ¹, Daniela Gomes Dos Reis ², Linaena Mericy da Silva Fonseca ¹, Sérgio Vitorino Cardoso ¹, Jackeline Alvarez Leite ³, Maria Auxiliadora Vieira do Carmo ¹

(1) DDS, PhD. Department of Oral Pathology, School of Dentistry

(2) graduate student. Department of Oral Pathology, School of Dentistry

(3) DDS, PhD. Department of Biochemistry and Immunology, Biological Sciences Institute. Federal University of Minas Gerais, Brazil

Correspondence:

Prof.^a. Dr.^a. Maria Cássia Ferreira de Aguiar

Universidade Federal de Minas Gerais

Laboratório de Patologia Experimental 1 (Sala 3201)

Faculdade de Odontologia

Av. Antônio Carlos, 6627

CEP: 31270-901 – Belo Horizonte (MG), Brazil

E-mail: mcaguiar@odonto.ufmg.br

Received: 16-12-2005

Accepted: 8-02-2006

Indexed in:

-Index Medicus / MEDLINE / PubMed
-EMBASE, Excerpta Medica
-Índice Médico Español
-IBECs

Ferreira-de Aguiar MC, Gomes-Dos Reis D, da Silva-Fonseca LM, Vitorino-Cardoso S, Alvarez-Leite J, Vieira-do Carmo MA. Immunohistochemical evaluation of metallothionein in palatal mucosal cells of mice treated with 4NQO. *Med Oral Patol Oral Cir Bucal* 2006;11:E315-8.

© Medicina Oral S. L. C.I.F. B 96689336 - ISSN 1698-6946

ABSTRACT

Objective: Metallothionein (MT) may play a preventive role in various carcinogenic process. 4NQO is an alkaline compound and potent mutagen that causes the formation of DNA adducts. The purpose of this study was to evaluate the immunoexpression of MT in palatal cells of mice submitted to the carcinogen 4NQO. **Study design:** C57BL/6 mice received applications of 4NQO to palate for periods of 8, 16, 20 and 24 weeks (experimental group). A control group received only applications of propylene glycol for the same periods. Subsequently animals of experimental and control groups were sacrificed and the palate was histologically analysed and MT immunohistochemistry performed. **Results:** Although morphological atypical features were scant, the expression of MT was higher in the experimental group in comparison to controls. There was an amplified induction of MT expression in oral epithelium of mice treated by 4NQO. **Conclusion:** These results suggest that MT may act as an endogenous defensive factor against 4NQO in early phases of oral carcinogenesis.

Key words: *Metallothionein; 4-NQO; squamous cell carcinoma; immunohistochemistry; oral carcinogenesis.*

INTRODUCTION

The mechanism involved in transformation of a normal cell into a malignant phenotype cell is not completely understood. Cancer appears after a permanent DNA injury by exposure to mutagenic agents or by spontaneous mutation. Chemical carcinogens are apparently responsible for the majority of human neoplasias and are directly involved in the aetiology of oral carcinoma (1, 2). The understanding of the early events involved in the pathogenesis of the oral squamous cell carcinoma is an important research priority (2, 3).

Experimental models have been used to study the effect of carcinogens and the evolution of neoplastic changes in oral mucosa (4). 4-nitroquinoline 1-oxide (4NQO) is a potent

chemical carcinogen that exhibits potent and pleiotropic carcinogenic effects on various species of animals. 4NQO is converted *in vivo* to 4 hydroxyaminoquinoline 1- oxide (4HAQO) and then to a highly reactive metabolite, seryl-4HAQO-tRNA synthetase to form a guanine and adenine adduct. If these modified bases are not appropriately repaired, erroneous genetic information is fixed to induce mutation or carcinogenesis (5).

Wallenius & Lekholm (6) reported that tumours could be produced in palatal mucosa of rats after repeated 4NQO solution application. Since then, many studies have shown induction of squamous cell carcinoma in superior aerodigestive tract sites (e.g. tongue and palate) of experimental animals by 4NQO administration (7,8,9). The production

of oral mucosal neoplasias in mice with 4NQO has also been demonstrated (10,11).

Metallothioneins (MT) are small non-enzymatic cysteine-rich proteins that have been considered to protect cells against chemical and radiation toxicity (12). The underlying mechanism for this function has not been entirely elucidated. Its ability to strongly bind and thereby inactivate hazardous compounds (e.g. heavy metals, free-radicals, anti-neoplastic drugs) has been suggested as fundamental for this action (13). Involvement in apoptotic pathways and in the regulation of transcription factor activity has also been proposed (14). Other studies on MT in neoplasias investigate its value as a prognostic factor (15). Notwithstanding worsening the prognosis of cancer, MT ambiguously protects normal cells against carcinogens probably by the same obscure mechanisms that render protection to transformed cells (16). This action on the normal oral epithelium against genotoxicity has not been evaluated yet, but it is known that in normal epithelium, MT immunoreaction is restricted to basal cells (17). The conservation of antigenic determinants among human, murine and equine species allows the use of commercially available antibodies in animal experimental research (18).

The purpose of the present study was to examine the effect of 4NQO on the tissue morphology and the immunohistochemical expression of MT in oral palatal mucosa of mice exposed to that carcinogen.

MATERIAL AND METHODS

Animals and study design

Forty-eight male C57 Bl/6 mice, 2 months old and weighing about 25g were used in this study. Animals were kept in plastic cages, six mice per cage, and received water and food *ad libitum*. Ethical approval was obtained from the Scientific and Ethical Committee (Ethics Committee in Animal Experimentation – CETEA - Federal University of Minas Gerais, Brazil). The experimental group (24 animals) received the 4NQO diluted to 0.5% in propylene glycol (PEG) three times a week, applied to the palate with a microbrush. The control group received only PEG. Six animals of each group were killed at different periods (8, 16, 20 and 24 weeks) by cervical dislocation, after sedation with commercial ether solution, and immediately dissected. Palate was removed, stored in 10% formaldehyde for 48 hours and then processed and embedded in paraffin.

Histological and immunohistochemical evaluation

Histological sections of 4 µm were stained by haematoxylin and eosin. The slides were evaluated by two expert pathologists (MAVC and MCFA). Immunohistochemical reactions for detection of MT were performed with the monoclonal antibody E9 (Dako Co., Carpinteria, CA, USA). Sections of 4 µm were placed in pretreated slides (3-aminopropyltriethoxy-silano). This was followed by deparaffination, hydration, and blocking of intrinsic enzymatic activity (peroxidase depleted with 10% H₂O₂). Then, slides were immersed in 1 M ethylenediamine tetraacetic acid (EDTA)

buffer, pH 9, and submitted to three cycles of 5 minutes in a microwave oven. After cooling and washing in distilled water, sections were subsequently incubated in primary antibody for MT (1:100 dilution), 18 hours at room temperature. After washing in distilled water, the slides were incubated in secondary biotinylated antibody (Multilink, Biogenex, San Ramon, CA, USA) 1:20 peroxidase complex (Dako, 1:100 dilution) for 30 min. Reactions were revealed by peroxidase activity in diaminobenzidine (DAB) chromogene substrate. The index for evaluation of MT immunostaining (IMT) was constructed based on a percentage of labelled cells among 200 suprabasal cells. Basal cells were not considered since basal layer cells are all positive for MT (17). This number was determined previously as the stabilization point of a cumulative percentage curve. Comparison of the IMT between and within experimental and control groups at different time intervals were analysed by Kruskal-Wallis test using the software SigmaStat (Jandel Co.; San Rafael, Calif., USA). Statistical significance was set at $p < 0.01$.

RESULTS

Histopathological results:

Microscopic findings included a higher frequency of basilar hyperplasia, nuclear hyperchromatism and increased mitotic activity in the group treated with 4NQO in comparison to controls. There were no obvious differences among periods of application of the 4NQO.

Neither carcinomas nor macroscopic changes could be observed in the control or experimental groups during the period of carcinogen application.

METALLOTHIONEIN IMMUNOHISTOCHEMISTRY

Immunohistochemical staining of MT was sometimes observed to be restricted to the nucleus, sometimes to the cytoplasm and was sometimes found in both compartments, with different intensities between positive cells, showing a characteristic mosaic pattern (Figure 1).

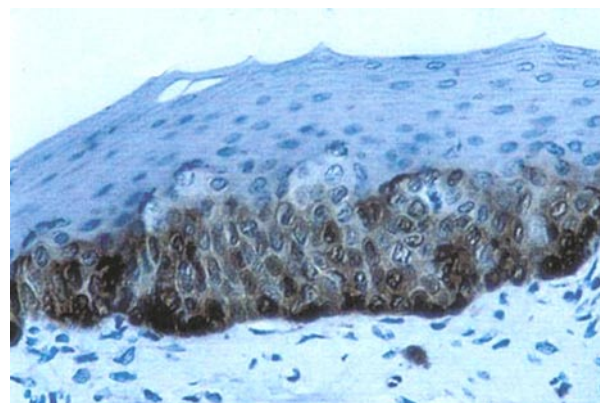


Fig. 1. MT immunostaining in experimental group with suprabasal and basal cells showing an intense reaction (streptavidin-biotin-peroxidase, 400X).

Both basal and parabasal cells were stained, but only supra-basal cells were considered in the counting. Mean IMT was always higher in experimental groups compared to controls due to higher numbers of immunoreactive cells with both cytoplasmic and nuclear staining. There was no clear increase of MT positivity related to the period of carcinogen application within groups, however, statistically significant differences were observed comparing experimental against control groups. MT index in all groups studied at different times are summarized in table 1.

Table 1. Means of Metallothionein immunolabelling cells in the studied groups, at different periods of 4NQO application (*p<0.01)

4NQO application	Means \pm SD	
	Control	4NQO
8 weeks	0,27 \pm 0,08 ^(a)	0,48 \pm 0,06 ^(e)
16 weeks	0,24 \pm 0,14 ^(b)	0,40 \pm 0,04 ^(d)
20 weeks	0,22 \pm 0,08 ^(c)	0,34 \pm 0,14 ^(g)
24 weeks	0,23 \pm 0,05 ^(d)	0,36 \pm 0,05 ^(h)

(a,b):n.s.; (a,c): n.s.; (a,d):n.s.; (b,c):n.s.; (b,d):n.s.; (c,d):n.s.; (a,e): p<0,01; (a,f):p<0,05;

(a,g):n.s.; (a,h):n.s.; (b,e):p<0,01; (b,f):p<0,05; (b,g):n.s.; (b,h): n.s.; (c,e):p<0,01; (d,e):p<0,01; (d,f):p<0,01; (d,g):p<0,05; (d,h):p<0,01; (e,f):n.s.; (e,g):n.s.; (e,h):n.s.; (f,g):n.s.; (f,h):n.s.; (g,h):n.s.

DISCUSSION

In the process of carcinogenesis, studies with molecular markers have allowed for early identification of changes before the appearance of the phenotypic dysplastic changes (3). Some authors have reported early irreversible changes in the oral mucosa of mice during treatment with 4NQO culminating with cancer (10,11). In spite of this, the progression of early lesions until oral carcinoma was not expected in this work. Considering the higher production of TNF α by C57 strain, some authors have stressed that carcinomas in this model were produced only after 50 weeks of exposure to the carcinogen (19,20). So, we focused only in the early alterations of oral palatal mucosa treated with 4NQO and their possible correlation with MT expression.

The present study shows amplified induction of MT expression in oral epithelium of mice treated by 4NQO although it only demonstrated scant histological alterations. In fact, cells with initial DNA damage may not show morphological alterations for an uncertain period of time. MT protects normal cells against carcinogens (16) and this may be the reason for an amplified imunoexpression of this protein in oral epithelium of mice treated by 4NQO. It also corroborates the speculated protective role of MT against other oral carcinogens (e. g. tobacco products). In fact, smoking has been associated with stimulation of MT production *in vitro* and *in vivo* (21). Increased MT expression has been shown in gingival tissues of smokers (22). Extrapolation of our

results suggests a protective function for MT in humans since chemical toxicity is the most important mutagenic mechanism associated with intra-oral carcinogenesis. DNA is a target molecule for 4NQO and its metabolites which form adducts within the genome favoring mutagenesis and tumour formation (5). Oxidative stress is thought to play a pro-carcinogenic role in carcinomas caused by 4NQO (23,24). MT can confer protection against oxidative damage on a specific target, such as DNA (25,26). This could help to explain the observation of a higher number of immunoreactive cells with cytoplasmic and nuclear staining in the experimental group compared to controls. In this case, we suggest the combined high nuclear concentration of MT and its excellent hydroxyl scavenger properties confer protection to DNA from hydroxyl radical attack.

Several lines of studies indicate that MT plays a role in carcinogenesis (16,25,27): MT genes are highly inducible by a variety of stress conditions which is a typical response of cellular defense (12); MT presents multiple thiol groups which render a strong scavenger property to this molecule, not only to metals, to which MT binds avidly, but also to metabolites that may be carcinogenic, such as 4NQO adducts (12,16). The extent and dynamic of this binding could determine to some extent the vulnerability to tumour development. Finally, other studies have demonstrated a possible role for MT in modulating spontaneous mutagenesis (28). In this case, low MT expression in tissues might be a risk factor for cancer.

The present results show an increase of MT immunohistochemical staining in oral mucosa of mice exposed to carcinogen 4NQO. This may suggest a protective function for MT in early stages of carcinogenesis in this model.

REFERENCES

1. Scully C, Field JK, Tanzwa H. Genetic aberrations in oral or head and neck squamous cell carcinoma (SCCHN): 1. carcinogen metabolism, DNA repair and cell cycle control. *Oral Oncol* 2000;36:256-63.
2. Martinez-Conde R, Aguirre JM, Burgos JJ, Rivera JM. Clinicopathological factors in early squamous cell carcinoma of the tongue and floor of the mouth, in Biscay (the Basque Country, Spain). *Med Oral* 2001;6:87-94.
3. Chimenos-Küstner E, Font-Costa I, López-López J. Oral cancer risk and molecular markers. *Med Oral Patol Oral Cir Bucal* 2004;9:377-84.
4. Eveson JW. Animal models of intra-oral carcinogenesis: a review. *J Oral Pathol* 1981;10:129-46.
5. Kitano M. Host genes controlling the susceptibility and resistance to squamous cell carcinoma of the tongue in a rat model. *Pathol Int* 2000;50:353-62.
6. Wallenius K, Lekholm U. Oral cancer in rats induced by water soluble carcinogen 4-nitroquinoline 1-oxide. *Odont Revy* 1973;24:39-48.
7. Ohne M, Satoh T, Yamada S, Takai H. Experimental tongue carcinoma of rats induced by oral administration of 4-nitroquinoline 1-oxide (4-NQO) in drinking water. *Oral Surg Oral Med Oral Pathol* 1985;59:600-7.
8. Svensson S, Heyden G. Experimental induction of irreversible precancerous changes in the palatal epithelium of the rat. *Int J Oral Surg* 1982;11:52-8.
9. Kaplan I, Hochstadt T, Dayan D. PCNA in palate and tongue mucosal dysplastic lesions induced by topically applied 4NQO in desalivated rat. *Med Oral* 2002;7:336-43.
10. Steidler NE, Reade PC. Experimental induction of oral squamous cell carcinomas in mice with 4-nitroquinoline-1-oxide. *Oral Surg Oral Med Oral Pathol* 1984;57:524-31.
11. Steidler NE, Reade PC. Initiation and promotion of experimental oral

- mucosal carcinogenesis in mice. *J Oral Pathol* 1986;15:43-7.
12. Coyle P, Philcox JC, Carey LC, Rofe AM. Metallothionein: the multipurpose protein. *Cell Mol Life Sci* 2002;59:1-21.
 13. Palmiter RD. The elusive function of metallothioneins. *Proc Natl Acad Sci* 1998;95: 8428-30.
 14. Li Y, Wo JM, Cai L, Zhou Z, Rosenbau D, Mendez C, et al. Association of metallothionein expression and lack of apoptosis with progression of carcinogenesis in Barret's esophagus. *Exp Biol Med* 2003;228:286-92.
 15. Cardoso SV, Barbosa HM, Candellori IM, Loyola AM, Aguiar MCF. Prognostic impact of metallothionein on oral squamous cell carcinoma. *Virchows Arch* 2002;441:174-8.
 16. Caherian MG, Huang PC, Klaasen CD, Liu YP, Longfellow DG, Wallkes MP. National Cancer Institute workshop on the possible roles of metallothionein in carcinogenesis – Meeting report. *Cancer Res* 1993;53: 922-5.
 17. Muramatsu Y, Hasegawa Y, Fukano H, Ogawa T, Namuba M, Mouri K et al. Metallothionein immunoreactivity in head and neck carcinomas; special reference to clinical behaviors and chemotherapy responses. *Anticancer Res* 2000;20:257-64.
 18. Nakajima K, Suzuki K, Otaki N. Epitope mapping of metallothionein antibodies. *Methods Enzimol* 1993;205:174-89.
 19. Takahashi K, Kubo T, Goomer RS, Amiel D, Kobayashi K, Imanishi J et al. Analysis of heat shock proteins and cytokines expressed during early stages of osteoarthritis in a mouse model. *Osteoarthritis Cartilage* 1997;5:321-9.
 20. Gannot G, Buchner A, Keisari Y. Interaction between the immune system and tongue squamous cell carcinoma induced by 4-nitroquinoline N-oxide in mice. *Oral Oncol* 2004; 40:287-97.
 21. Milnerowicz H, Slowinska M. Concentration of metals, ceruloplasmin, metallothionein and the activity of N-acetyl-beta-D-glucosaminidase and gamma-glutamyltransferase in pregnant women who smoke and in those environmentally exposed to tobacco smoke and in their infants. Part I. *Int J Occup Med Environ Health* 1997;10:187-202.
 22. Katsuragi H, Hasegawa A, Saito K. Distribution of metallothionein in cigarette smokers and non-smokers in advanced periodontitis patients. *J Periodontol* 1997;10:1005-9.
 23. Nunoshiro T, Dimple B. Potent intracellular oxidative stress exerted by the carcinogen 4-nitroquinoline-N-oxide. *Cancer Res* 1993;53:3520-2.
 24. Yano T, Takahashi S, Ishikawa T. Active oxygen generated in the process of carcinogen metabolism can induce oxidative damage in nuclei. *Res Commun Mol Pathol Pharmacol* 1995;87:367-70.
 25. Chubatsu LS, Meneghini R. Metallothionein protects DNA from oxidative damage. *Biochem J* 1993;291:193-8.
 26. Lazo JS, Kuo SM, Woo ES, Pitt BR. The protein thiol metallothionein as an antioxidant and protectant against antineoplastic drugs. *Chem Biol Interact* 1998;111-112:197-201.
 27. Hanada K, Sawamura D, Tamai K, Baba T, Hashimoto I, Muramatsu T, et al. Novel function of metallothionein in photoprotection: metallothionein-null mouse exhibits reduced tolerance against ultraviolet B injury in the skin. *J Invest Dermatol* 1998;111:582-5.
 28. Goncharova EI, Rossman TG. A role for metallothionein and zinc in spontaneous mutagenesis. *Cancer Res* 1994;54:5318-23.